

# OVERVIEW

## The Lingual Frenum

MICHAEL E. NORTHCUTT, DDS

---

*(Editor's Note: In this quarterly column, JCO provides an overview of a clinical topic of interest to orthodontists. Contributions and suggestions for future subjects are welcome.)*

---

**A** frenum is a small muscle, covered by a mucous membrane, that attaches the lips and tongue to the adjacent bones in the mouth. Normally, there are seven oral frenums: the maxillary midline frenum, the mandibular midline frenum, the right and left upper and lower labial frenums, and the lower lingual frenum. There is no set limit, however, and considerable variation can be observed in normal frenum shape and position (Fig. 1). The primary function of frenums is to keep the lips and tongue in harmony with the growing bones of the mouth during fetal development. An aberrant frenum, which is a congenital anomaly, can be familial<sup>1</sup> and is more common in boys than in girls.<sup>2</sup> Even though aberrant frenums are associated with

significant orthodontic problems,<sup>3</sup> the topic is not emphasized in orthodontic training, and little has been written on the subject.

A deviant frenum can be treated by clipping (frenotomy) or by surgical excision and removal of a substantial portion of the underlying muscular tissue (frenectomy). An anterior or labial frenotomy often requires only a local anesthetic and a small clip or incision. A frenectomy should always be performed rather than a frenotomy on a thick frenum because of the pronounced tendency of a frenum to scar after surgery. Since this can produce a new frenum that is shorter than the original, if the surgery is not thorough enough, the outcome can be unsatisfactory (Fig. 2). Z-plasty surgery<sup>4</sup> is sometimes required on thicker, more complicated lower lingual frenums.

Lingual frenectomy involves the removal of a triangular wedge, including all remnants of the frenum from the lingual salivary gland to the intersection of the frenum with the underside of the tongue<sup>5</sup> (Fig. 3). In severe cases, the fibers of the frenum should be removed all the way to the tip of the tongue. After surgery, the tongue should be able to extend down the chin to cephalometric "B" point.

A frenum that attaches too close to the gingival margin of a tooth can cause gingival detachment<sup>6</sup> and resultant loss of bone. Figure 4 shows a patient with blanching of the gingiva around the maxillary anterior teeth. A slight lift of the upper lip creates sufficient tension on the upper midline frenum to cause gingival recession, rotation, diastema, and eventually bone loss. If the frenum is short and broad, it can tie down the upper lip



Dr. Northcutt

---

Dr. Northcutt is in the private practice of orthodontics at 563 Brunswick Road, Suite 10, Grass Valley, CA 95945.

and prevent the patient from smiling easily. A maxillary frenectomy is definitely indicated in such a case, with the fibers surgically removed all the way through to the palate and down to the bone. All frenum fibers between the two upper central incisors should be removed completely.

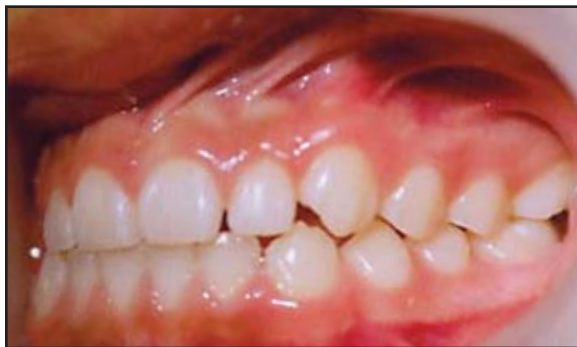**The Lingual Frenum**

Two elements of physiology are essential to understanding the influence of the lingual frenum on the dentition: first, muscles determine the shape of bone; and second, food is swallowed by vacuum force in the mouth. To create a vacuum, the tongue is normally elevated to the roof of the mouth, creating a seal and giving the palate its normal shape.<sup>7</sup> The lingual frenum acts more like a tendon than a muscle; small as it is, it rigidly establishes the height to which the tongue can rise. When upward tongue movement is restricted due to a short lingual frenum, the tongue must thrust forward to create a seal at the front of the mouth, often causing maxillary protrusion and anterior open bite. The tongue’s vertical height appears to be locked at or near the first contact of the frenum with the underside of the tongue.

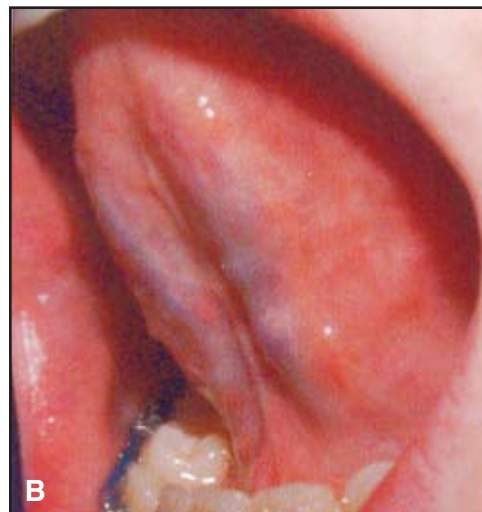
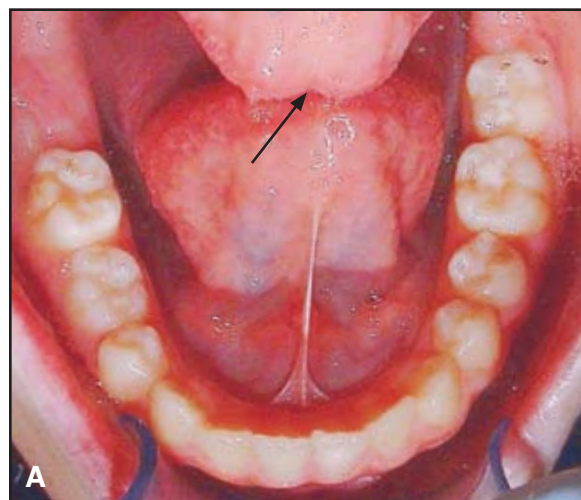
This dynamic can be observed by attempting to swallow when upward motion of the tongue is restricted (such as when a pencil is placed between the back teeth). The tongue will thrust forward, as opposed to normal swallowing, when the flat dorsum of the tongue presses against the palate. During growth and development, upward pressure

of the tongue creates the width and shape of the palate. If the lower lingual frenum is short, the tongue will not generate enough upward pressure to create a normal palate, and a narrow and underdeveloped palate will result (Fig. 5).

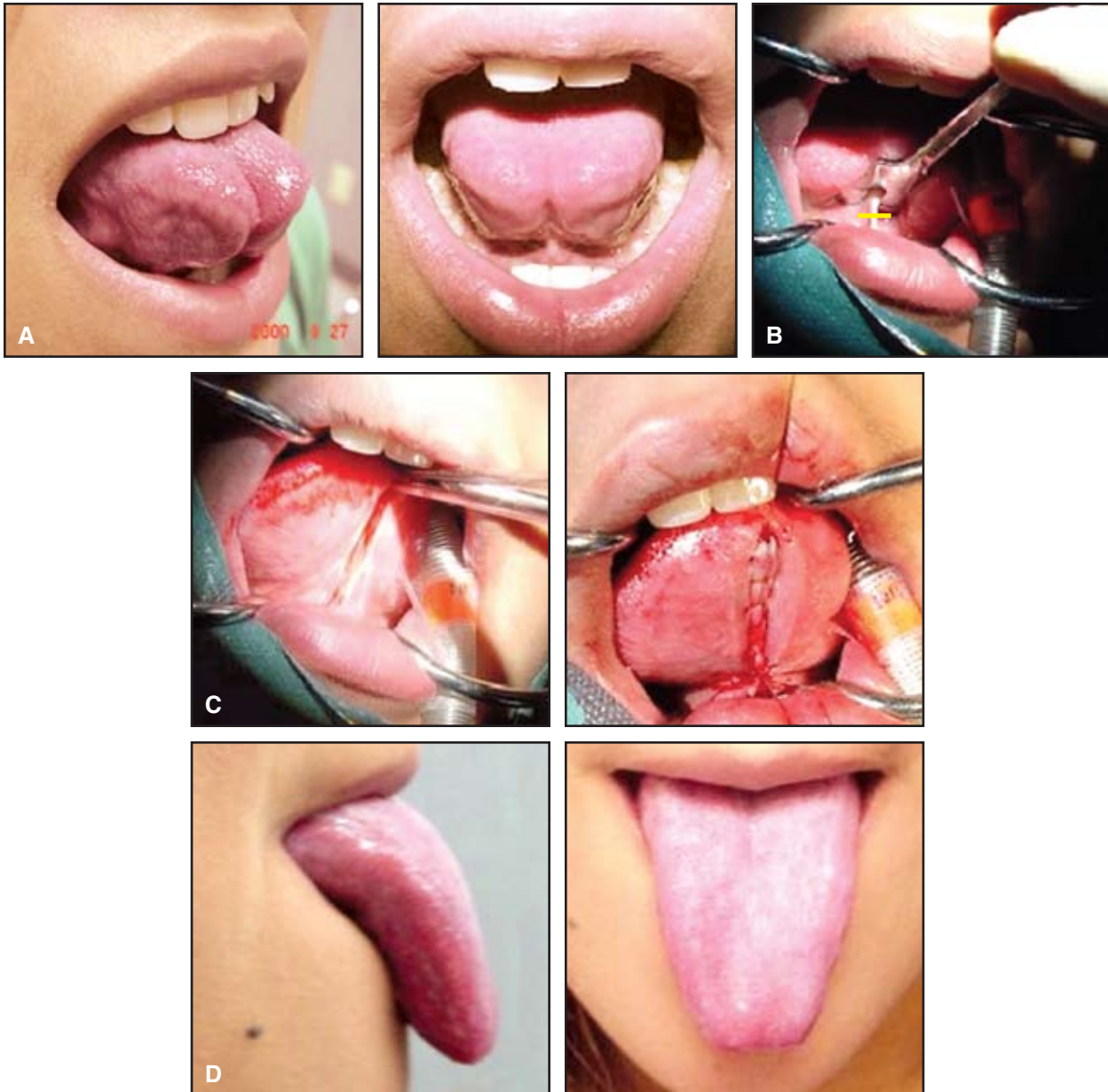
A short lower lingual frenum (“tongue-tie”) is known as ankyloglossia. Kotlow’s four classes



**Fig. 1** Normal patient with multiple labial frenums.



**Fig. 2** A. Patient with frontal and bilateral tongue thrust, constricted maxilla, and bilateral crossbite attributable to short lingual frenum. B. One year after frenectomy, remnant of lingual frenum has reattached due to scarring. Frenum is still strong enough to create sulcus running entire length of tongue.



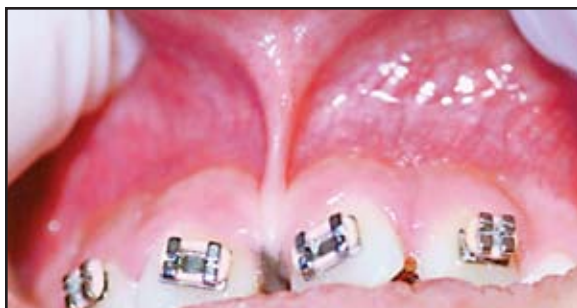**Fig. 3** A. Patient before frenectomy. B. Exposure of frenulum; horizontal line indicates location of incision. C. Frenum pulled vertically and sutured with resorbable stitches. D. After surgery, patient can extend tongue to cephalometric "B" point. (Photo series reproduced by permission of Dr. Bechara Y. Ghorayeb, Houston, TX.)



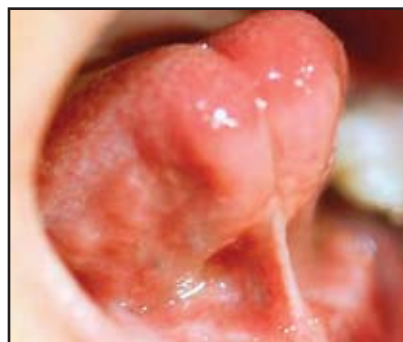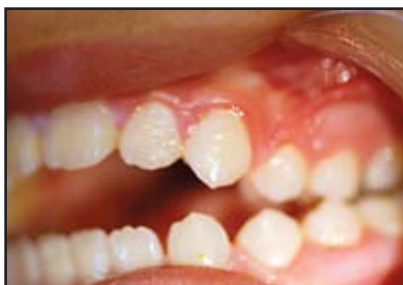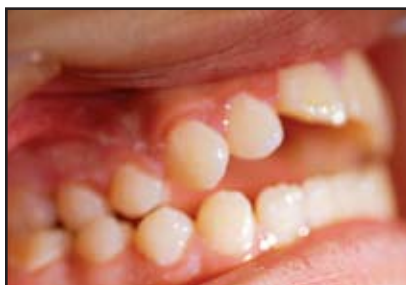of ankyloglossia are based on the distance from the tip of the tongue to the attachment of the frenum.<sup>8</sup> A distance of 16mm is considered normal, while Classes 1 to 4 are associated with decreasing distances and increasing severity of dysfunction: Class 1 = 12-16mm (mild); Class 2 = 8-11mm (moderate); Class 3 = 3-7mm (severe); Class 4 = attachment at the tip of the tongue (very severe). Another system, the Tongue-Tie Assessment Protocol,<sup>9</sup> provides a method for scoring the functional and cosmetic effects of a short lingual frenum, which can be helpful in determining whether surgical intervention is warranted.

**Clinical Study**

I recently performed an informal visual assessment of tongue shape and lingual frenums in 600 individuals with Class I malocclusions from a single pedodontic practice, over the course of 18 months. Patients were asked to open their



**Fig. 4** Patient with thick labial frenum at maxillary midline, causing diastema and tooth rotations.



**Fig. 5** Maxillary protrusion and open bite caused by tongue-thrust habit, likely due to short lingual frenum.

**TABLE 1  
BREAKDOWN OF VISUAL  
ASSESSMENT FINDINGS (N=600)**

	Number of Patients	Percentage of Total
Male	216	36%
Female	384	64%
N-1 frenum	214	36%
N-2 frenum	188	31%
N-3 frenum	194	32%
N-4 frenum	4	1%
Maxillary constriction	502	84%
Maxillary protrusion	438	73%
Spacing	198	33%
Crowding	482	80%
Open bite	312	52%
Deep bite	120	20%

mouths as wide as possible and then touch the tips of the upper central incisors with the tips of their tongues. The shape of the tongue, length of the frenum, and nature of malocclusion were recorded for each patient.

Several limitations of this study should be noted at the outset: All patients had Class I malocclusions, and more than 95% were of Mexican descent. All patients came from the same dental practice and were evaluated by the author. Additional studies are needed with unbiased patient selection (including a control group without malocclusion), sampling from diverse ethno- and geographical patient groups and controlling for perceptual bias of the examiner. Long-term twin studies might also be useful.

In the present sample, lingual frenums were classified as N-1 to N-4, in order of increasing severity, based solely on appearance. Without

exception, the presence of ankyloglossia was associated with the presence of malocclusion, as detailed in Table 1.

An **N-1** frenum constrains the normal mobility of the tongue, limiting its ability to reach the incisal edges of the upper anterior teeth when the mouth is wide open (Fig. 6). Although an N-1 frenum does not distort the shape of the tongue or create an invagination at the tongue tip, it is strong enough to hold down the dorsum of the tongue, preventing it from rising to shape the palate. The narrow palate creates a short arch perimeter, resulting in crowding and rotations, crossbite, open bite, and anterior or lateral tongue thrust.

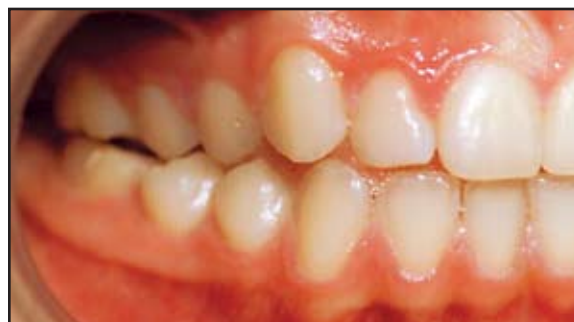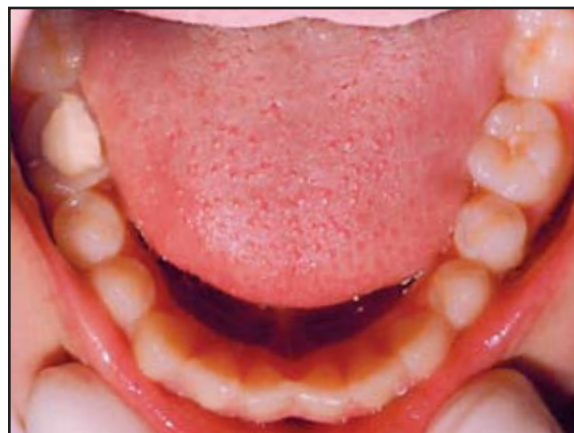An **N-2** is a short lingual frenum, stronger than an N-1 and usually thick. An N-2 frenum pulls on the tongue with sufficient force to form a sulcus at the tip or on the underside of the tongue (Fig. 7).

An **N-3** frenum, which is shorter and stronger than an N-2, creates sufficient force to distort the whole tongue, forming a pronounced “U” or “V” shape at the tip (Fig. 8).

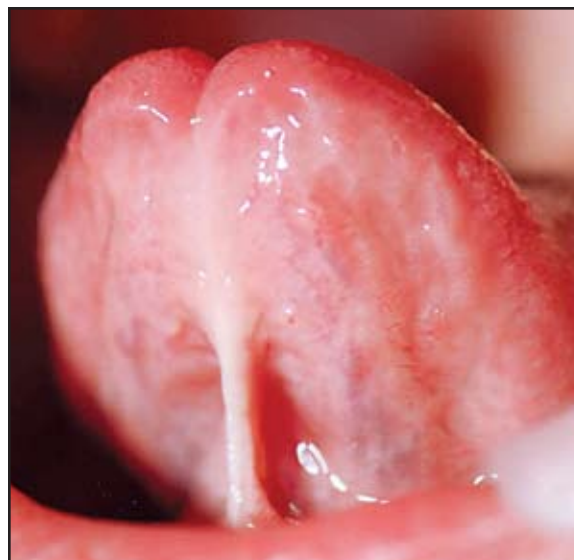The **N-4** frenum is attached to the tip of the tongue (Fig. 9) and often affects speech. Ironically, however, the shortest frenums don't cause the greatest harm to the dentition. Unlike N-1 and N-2 frenums, N-3 and N-4 frenums don't always create tongue thrust because the tongue tip is tied down and thus cannot push the upper teeth up and out. The N-1 and N-2 frenums are somewhat longer and therefore allow the tongue to push out farther, causing more damage to the anterior teeth.

### Crowding and Arch Width

A narrow arch has a shorter perimeter than a wide arch, creating a shortage of space and buccal and/or anterior crowding. Sometimes this crowding will be horizontal, flaring the teeth forward. In a normal occlusion, the edges of the upper teeth lie outside the edges of the lower teeth, thus “containing” the lower arch. When an upper arch is narrow, however, the lower arch will be constrained in its development, often resulting in lingual tipping of the posterior teeth (Fig. 10) or development of a crossbite.



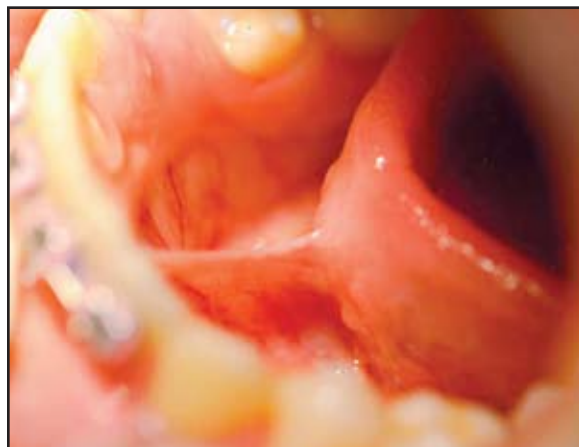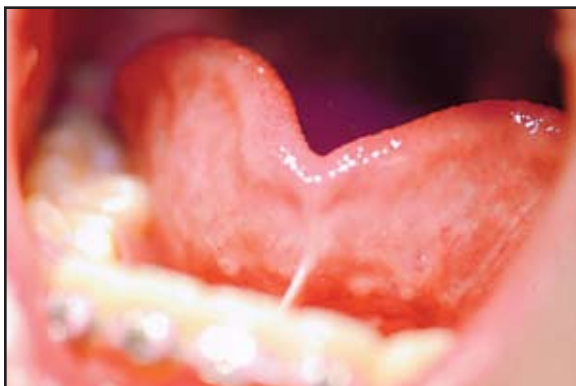
**Fig. 6** N-1 frenum. Patient's tongue is constrained from reaching incisal edges of upper incisors, but is not distorted when extended. Because of reduced transverse width, patient developed accommodation bite on left side and crossbite on right side.



**Fig. 7** N-2 frenum. Frenum is short and usually thick, pulling on tongue with sufficient force to form sulcus at tip of tongue. Frenectomy will be required in this case, including excision of frenum fibers as far as tongue tip.

The tongue, like any muscle, depends on use to achieve its fullest potential growth. When tongue movements are constrained by ankyloglossia, palatal width is reduced. The premolars and molars, lacking transverse support, tip lingually, and thus smaller upper and lower arch circumferences are created, causing crowding of the anterior teeth (Fig. 11).

The upper buccal segments must be expanded for the lower buccal segments to become more upright. It follows that crowding in the lower arch necessitates expansion of the upper arch. If the lower buccal segments are not widened to create a longer perimeter, the only way lower crowding can be alleviated (save for extractions) is for the lower anterior teeth to dump forward. This creates

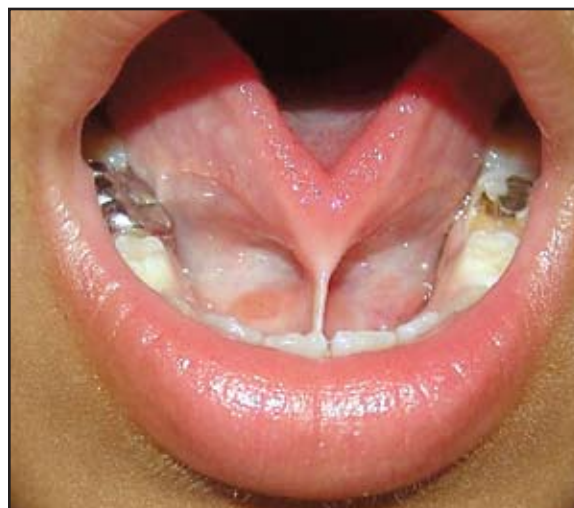

**Fig. 8 N-3 frenum.** Frenum is shorter and thicker than N-2, creating sufficient force to distort entire tongue.

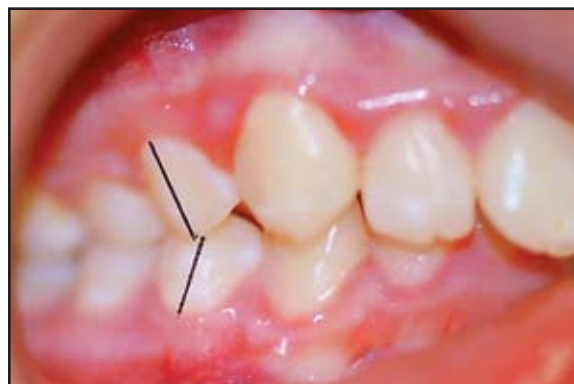an unstable situation over the long term.

For maxillary expansion, I recommend the spring-loaded Max-2000\* (Fig. 12). This expander can be direct-bonded, using bonding clasps made of heavy .060" stainless steel wire to avoid abutment tipping. Because the expansion springs

\*Dynaflex, 10403 International Plaza Drive, St. Ann, MO 63074; www.Dynaflex.com.



**Fig. 9 N-4 frenum.** Shortest and strongest of lingual frenums, this often affects speech. Tongue restriction as severe as shown here will require surgery (photo courtesy of Dr. Bechara Y. Ghorayeb).



**Fig. 10** Narrow maxillary arch constrains mandibular arch development, causing lingual tipping of lower posterior teeth.



are made of light nickel titanium open-coil wire, the appliance is less painful than traditional rapid palatal expansion, and no activations by the patient or parent are required. The starting width is maintained before cementation by two transverse chain elastics tied from clasp to clasp. During the try-in, the acrylic portion of the appliance is pressed firmly against the palate. Any springback means that a clasp is too tight or ill-fitting and needs to be bent down or otherwise adjusted until there is absolutely no springback. Following cementation, the transverse ties are cut, thus activating the appliance. Although many cements are acceptable for bonding the appliance, one exception is Transbond,\*\* which has a glass filler that is abrasive to the occlusal surfaces of the teeth in the opposing arch. Expansion is usually completed in three months or less.

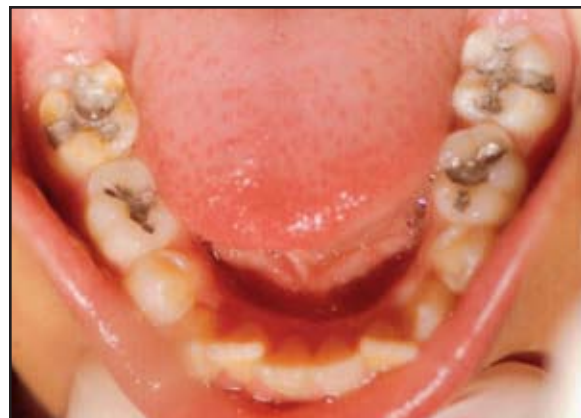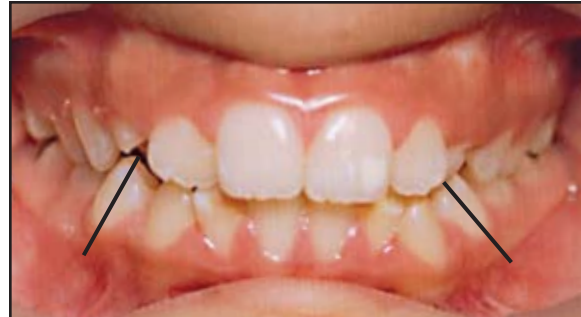Maxillary arch expansion will often relapse if a lower lingual frenectomy is not performed. It is not sufficient to treat the symptoms without treating the cause. When the lingual frenum is removed, both lower and upper relapse will be reduced.

### The N Point

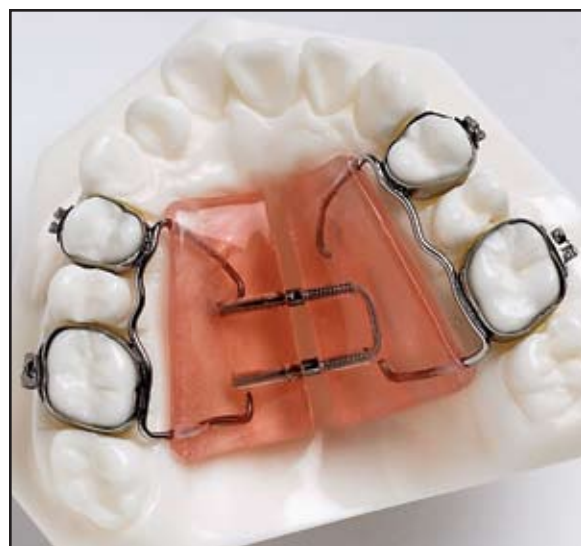Figure 13 shows an example of a patient with severe (N-2) ankyloglossia, in which a fold of the tongue is created an inch or so behind the tip. This is called the “N angle”; the point where the two legs of the angle come together is called the “N point”. The N point is where the tongue shifts from horizontal to vertical in the mouth upon extended opening or swallowing. Although it seems logical that a frenum pull from the front would roll the tongue forward and down rather than back, this is not what actually occurs. Distal to the N angle, the dorsum of the tongue lies flat, which indicates that the dorsum of the tongue is tied to the floor of the mouth by the lingual frenum. That prevents the tongue from rising up to give a natural shape and width to the palate.

The N-angular shift of the upper anterior teeth parallels the N angle of the tongue (Fig. 14),

\*\*3M Unitek, 2724 S. Peck Road, Monrovia, CA 91016; www.3Munitek.com..



**Fig. 11** Mandibular anterior crowding caused by constrained lateral tongue development, reducing arch width and transverse support for lower dentition.



**Fig. 12** Spring-loaded Max-2000 expansion appliance from Dynaflex.\*

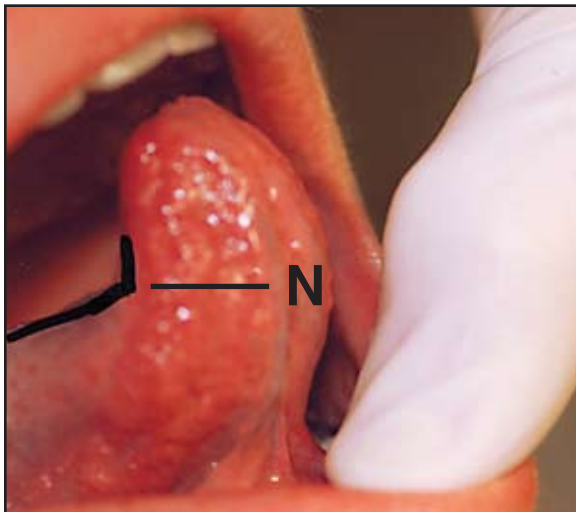


Fig. 13 Patient with N-2 frenum. Fold of tongue creates “N angle” and “N point”.

although a deviant form sometimes occurs laterally (Fig. 15). The N-point shift of the tongue is congruent with a shift point of the teeth and face, which strongly suggests a cause-and-effect relationship.

### Discussion

Orthodontic problems highly prone to relapse after treatment include palatal restriction,<sup>10</sup> tongue thrust,<sup>11</sup> and lower anterior crowding.<sup>12</sup> In a review of eight articles on maxillary expansion published between 1979 and 2005, Marshall and colleagues concluded that additional clinical trials were need-

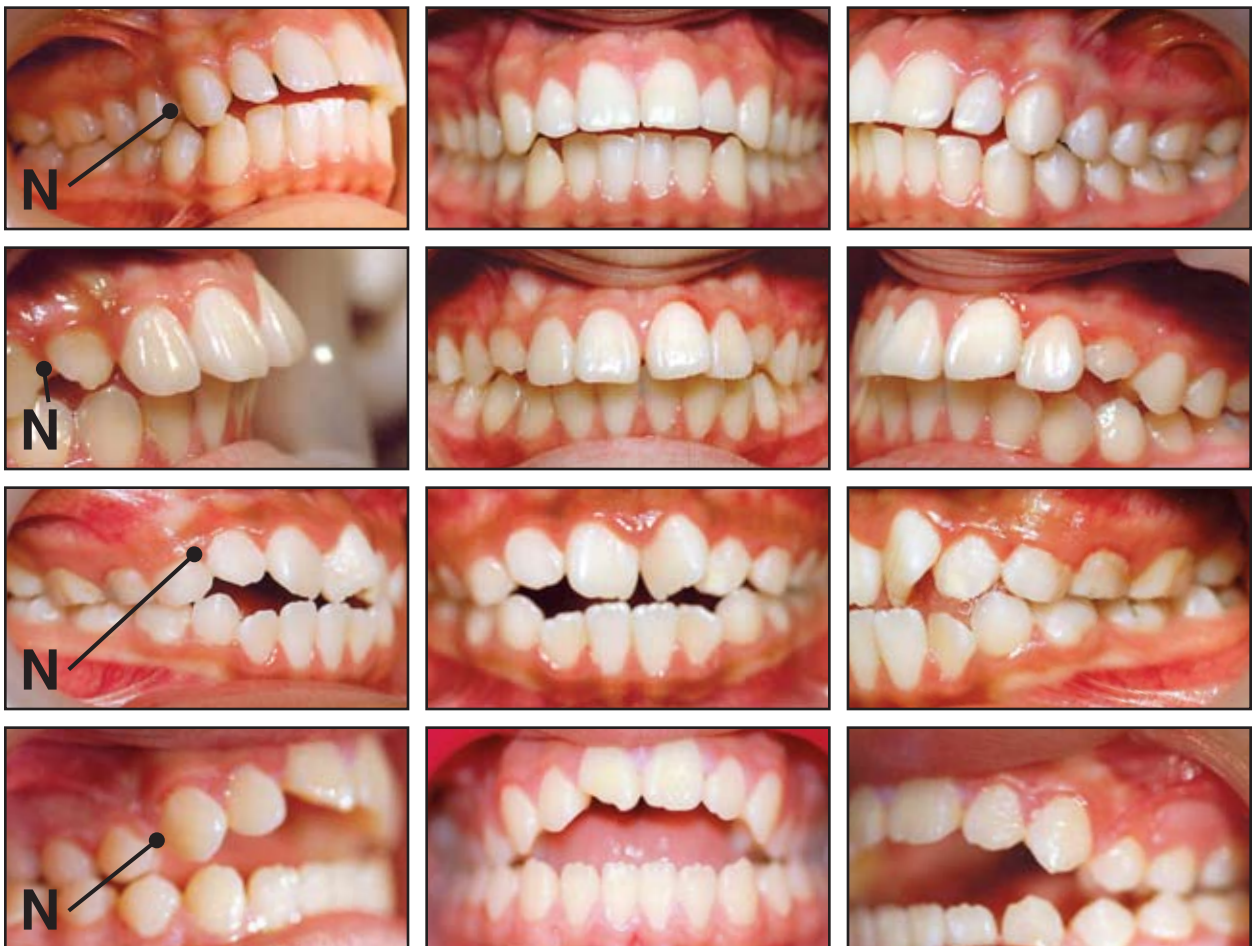
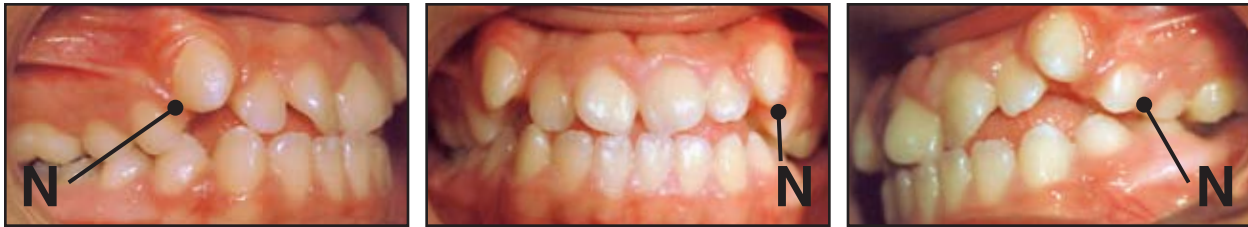
Fig. 14 N-angular shift of upper anterior teeth parallels N angle of tongue.





**Fig. 15 Lateral variation of N-angular shift of upper anterior teeth.**

ed to establish whether maxillary expansion can be stable in adolescent patients with pre-existing crossbites.<sup>13</sup> A similar view was expressed by Mulligan, who observed that frequent relapse of maxillary or mandibular expansion treatment may be caused by teeth being “placed in positions that are not in equilibrium with their functional environment”.<sup>14</sup> Mulligan also noted that an aberrant frenum often plays a role in these cases. Defabianis suggested that failure to correct improper tongue function can have serious implications for facial development and can influence the outcome of orthodontic therapy.<sup>15</sup> She noted that patients with ankyloglossia who cannot afford orthodontic treatment might be helped by simple frenectomies.

Lingual frenectomy, when necessary, should be performed at the start of orthodontic treatment, so that long-established muscle patterns can be corrected to avoid negatively affecting the treatment outcome. This approach will help the patient develop new muscle patterns while under the care of an orthodontist.

A newborn should be examined and the need for frenectomy identified as soon as possible after birth. Early intervention to correct aberrant frenums will improve breastfeeding and avoid later problems with tooth and speech development.<sup>16</sup> Pediatricians and pedodontists should therefore be trained to recognize ankyloglossia and promote early treatment.

Recently developed local analgesics promise to reduce the discomfort associated with frenectomies.<sup>17</sup> In addition, a new technique using CO<sub>2</sub> laser technology has been developed that can make frenectomy simpler than many traditional surgical dental procedures.<sup>18</sup> Because of these advances, frenectomy can now be performed by a general dentist instead of a specialist.

## Conclusion

As a result of this study, the author would like to present to the orthodontic profession the hypothesis that ankyloglossia is the leading cause of non-skeletal orthodontic problems, along with

the following corollary: If the cause is not corrected, why should anyone be surprised by relapse?

ACKNOWLEDGMENT: The author thanks Dr. Siva Cherukuri, a pedodontist in Redwood City, CA, and her office manager, Sam Cherukuri, for facilitating and assisting with data collection for the preliminary study reported in this article.

## REFERENCES

1. Klockars, T.: Familial ankyloglossia (tongue-tie), *Int. J. Pediat. Otorhinolaryngol.* 71:1321-1324, 2007.
2. Messner, M.L.; Aby, J.; Macmahon, J.; and Bair, E.: Ankyloglossia: Incidence and associated feeding difficulties, *Arch. Otolaryngol. Head Neck Surg.* 126:36-39, 2000.
3. Palmer, B.: Frenums, tongue-tie, ankyloglossia, [www.brianpalmerdds.com/frenum.htm](http://www.brianpalmerdds.com/frenum.htm), 2001.
4. Heller, J.; Gabbay, J.; O'Hara, C.; Heller, M.; and Bradley, J.P.: Improved ankyloglossia correction with four-flap Z-frenuloplasty, *Ann. Plast. Surg.* 54:623-628, 2005.
5. Ghorayeb, B.Y.: Frenectomy photos, [www.ghorayeb.com/tonguetie.html](http://www.ghorayeb.com/tonguetie.html).
6. Toker, H. and Ozdemir, H.: Gingival recession: Epidemiology and risk indicators in a university dental hospital in Turkey, *Int. J. Dent. Hyg.* 7:115-120, 2009.
7. Moss, M.: The primary role of functional matrices in facial growth, *Am. J. Orthod.* 55:566-577, 1969.
8. Kotlow, L.A.: Ankyloglossia (tongue-tie): A diagnostic and treatment quandary, *Quintess. Int.* 30:259-262, 1999.
9. Fernando, C.: Assessment criteria, in *Tongue-Tie: From Confusion to Clarity*, Tandem Publications, Concord, Australia, 1998, pp. 17-20.
10. Vanarsdall, R.L. Jr.: Transverse dimension and long-term stability, *Semin. Orthod.* 5:171-180, 1999.
11. Janson, G.; Valarelli, F.P.; Beltrão, R.T.S.; Freitas, M.R.; and Henriques, J.F.C.: Stability of anterior open-bite extraction and nonextraction treatment in the permanent dentition, *Am. J. Orthod.* 129:768-774, 2006.
12. Little, R.M.: Stability and relapse of mandibular anterior alignment: University of Washington studies, *Semin. Orthod.* 5:191-204, 1999.
13. Marshall, S.D.; English, J.D. Jr.; Huang, G.J.; Messersmith, M.L.; Nah, H.D.; Riolo, M.L.; Shroff, B.; Southard, T.E.; Suri, L.; and Turpin, D.L.: Long term stability of maxillary expansion, *Am. J. Orthod.* 133:780-781, 2008.
14. Mulligan, T.: Diastema closure and long-term stability, *J. Clin. Orthod.* 37:560-574, 2003.
15. Defabianis, P.: Ankyloglossia and its influence on maxillary and mandibular development (A seven year follow-up case report), *Funct. Orthod.* 17:25-33, 2000.
16. Escott, R.: Positioning, attachment, and milk transfer, *Breastfeeding Rev.* 1:35, 1989.
17. Fromm, S.R. and Stewart, J.: Novel local anesthetic analgesic technique for tongue-tie, *Anesthesia* 62:97, 2007.
18. Bullock, N. Jr.: The use of the CO<sub>2</sub> laser for lingual frenectomy and excisional biopsy, *Compend. Cont. Ed. Dent.* 16:1118-1123, 1995.